

Review

# Current status of radioactive seed for localization of non palpable breast lesions

James W. Jakub, M.D., F.A.C.S.<sup>a,\*</sup>, Richard J. Gray, M.D., F.A.C.S.<sup>b</sup>,  
Amy C. Degnim, M.D., F.A.C.S.<sup>a</sup>, Judy C. Boughey, M.D., F.A.C.S.<sup>a</sup>,  
Mary Gardner, M.D.<sup>c</sup>, Charles E. Cox, M.D., F.A.C.S.<sup>d</sup>

<sup>a</sup>Department of Surgery, Mayo Clinic, Rochester, MN, USA; <sup>b</sup>Department of Surgery, Mayo Clinic, Scottsdale, AZ, USA; and Department of <sup>c</sup>Radiology and <sup>d</sup>Surgery, University of South Florida College of Medicine, Tampa, FL, USA

## KEYWORDS:

Breast cancer;  
Seed;  
Breast biopsy;  
Sentinel lymph node;  
Radioactive seed;  
Lumpectomy

## Abstract

**BACKGROUND:** Wire-localized breast biopsy (WLBB) remains the standard method for the surgical excision of nonpalpable breast lesions. Because of many of its shortcomings, most important a high microscopic positive margin rate, alternative approaches have been described, including radioactive seed localization (RSL). This review highlights the literature regarding RSL, including safety, the ease of the procedure, billing, and oncologic outcomes.

**METHODS:** Medline and PubMed were searched using the terms “radioactive seed” and “breast.” All peer-reviewed studies were included in this review.

**CONCLUSIONS:** RSL is a promising approach for the resection of nonpalpable breast lesions. It is a reliable and safe alternative to WLBB. RSL is at least equivalent compared with WLBB in terms of the ease of the procedure, removing the target lesion, the volume of breast tissue excised, obtaining negative margins, avoiding a second operative intervention, and allowing for simultaneous axillary staging.

© 2010 Elsevier Inc. All rights reserved.

## Current standard

With the increased utilization of mammographic screening programs, breast cancer is more frequently being detected as a radiographic lesion only. Additionally, the sizes of tumors detected have decreased in recent years, increasing the need for the accurate localization of small-volume disease. This has made image-directed localization a necessity for surgical excision in a significant portion of cases. Wire-localized breast biopsy (WLBB) is the most commonly used method for the surgical excision of nonpalpable breast lesions. Although WLBB has been the standard of care for many years, inherent problems remain. The major issues can be summarized as follows:

1. Microscopic margins are frequently positive, requiring additional operations.
2. The surgeon is often unable to confirm the exact site of a lesion in the breast.
3. Scheduling conflicts between the surgeon and the radiologist can occur, resulting from the need to coordinate multiple procedures on the same day with different teams.
4. There is an inability to use wire localization for the first start time in the morning without a significant delay in the operating room.

Because the wire exits the patient's skin and is located both internally and externally, surgical excision is almost universally performed on the same day as the localization procedure. This frequently leads to scheduling conflicts between radiology and surgery. The need for same-day localization in radiology also prohibits a first morning surgical start time and leads to inherent delays in costly oper-

\* Corresponding author. Tel.: 507-284-3629; fax: 507-284-5196.

E-mail address: jakub.james@mayo.edu

Manuscript received March 10, 2009; revised manuscript May 26, 2009

ating room time. The ideal skin entry site for the radiologist is often distant from the lesion, and therefore, the entry site of the wire is often remote from the wire tip and the target lesion. Intraoperatively, the surgeon's incision is placed on the basis of interpretation of the radiographs. This less than precise estimate by the surgeon of the ideal transcutaneous route to the lesion may result in the skin incision not being placed in the most desirable location. Therefore, the incision is frequently not over the tip of the wire and the lesion, resulting in extensive dissection in many cases. A WLBB procedure is not intuitive to the surgeon, because the tip of the wire cannot be visualized or palpated in the breast parenchyma. This leads to a nonuniform specimen in many cases, especially with regard to margins around the primary lesion. Often, the microscopic margins are close or positive in some locations and widely negative in others, resulting in the removal of excessive benign breast tissue. The incidence of positive microscopic margins has been reported in 20% to 70% of cases, and the need for reoperation remains high in most studies.<sup>1-5</sup>

Aside from these common issues, there remain serious problems, which fortunately are encountered infrequently. There are multiple steps in the process of WLBB that allow for the wire to be displaced from its originally intended site.<sup>6,7</sup> This can occur during patient transfer, at the time of confirmatory mammography following needle localization, and intraoperatively. Transection of the wire can also be a problem and has resulted in retained metal fragments in the breast.<sup>8-10</sup> Wire displacement or transection can result in the removal of excess breast tissue or, in extreme cases, an inability to excise the index lesion.<sup>6,11</sup> This is likely underreported in the literature. The wire may also act as a "wick," promoting the leakage of material that is injected peritumorally for sentinel lymph node (SLN) mapping. We have seen this with both blue dye and <sup>99</sup>Tc. Leakage of the radioactive material may result in skin contamination and confusion during SLN biopsy.

Despite all these shortcomings, wire localization remains the current standard for nonpalpable breast lesions that require surgical excision. Because of the limitations outlined above, many other approaches have been described as potential replacements to this procedure. These alternatives include radio-guided occult lesion localization, intraoperative ultrasound, and radioactive seed localization (RSL). In this review, we focus on RSL.

## Radioactive seed-localized lumpectomy

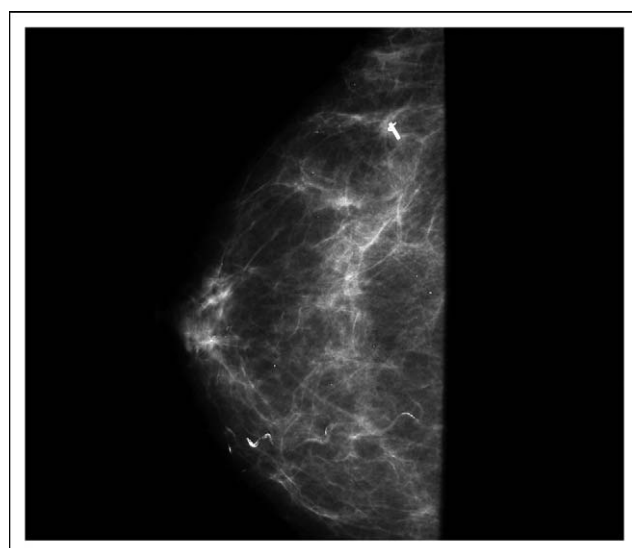
### Concept and technique

The radioactive seed is a titanium seed containing 3.7 to 10.7 MBq of <sup>125</sup>I, which has a half-life of 60 days and emits 27 keV of gamma radiation. Technetium-99, the isotope commonly used for SLN mapping, has a much shorter half-life (6 hours) but has stronger gamma emission of 140

keV. These characteristics allow for significant separation of peak radiation energy emission, and therefore these two gamma sources are separately identifiable even when near each other. This makes the <sup>125</sup>I seed an excellent source to be used in combination with the standard <sup>99</sup>Tc SLN technique.<sup>1,12</sup> Iodine-125 seeds are used routinely as interstitial treatment for prostate cancer. Despite multiple seeds (50–110) with higher activity (12.6–16.7 MBq) being placed during this procedure, there are minimal patient restrictions regarding radiation safety. In using the seeds for breast procedures, the seeds are used as the point sources for localization rather than as therapeutic devices. The source is in the patient for a limited time, and the dose is significantly less than for routine prostate therapy as outlined above.

The radioactive seed is introduced through an 18-gauge needle using standard ultrasound or mammographic guidance. The tip of the needle is occluded with bone wax, the radioactive seed loaded, and a stylette loosely placed into the needle. Once guided to the desired location of the breast lesion, the seed is deployed into the breast parenchyma through the bone wax by advancing the stylette. Mammography confirms appropriate placement (Fig. 1). Because of the long half-life of the seed, it can be placed weeks in advance of the surgical procedure. There is one report from The Netherlands of leaving the seed in for a prolonged period during neoadjuvant chemotherapy.<sup>13</sup> However, in practical terms, all protocols in the United States have the seed placed within 5 days of surgery.

Standard intraoperative handheld gamma probes used for SLN detection can be used to localize the <sup>125</sup>I seed. With the gamma probe detection systems currently used in most operating rooms, users can specify the detection of certain isotopes, including <sup>125</sup>I and <sup>99</sup>Tc, simply by pressing a button on the machine. This permits the selective detection of each isotope on the basis of the defined gamma emission peak for that isotope. Therefore, the detection of different



**Figure 1** Preoperative mammography confirming seed placement at the clip.



**Figure 2** Gamma probe settings to detect  $^{99m}\text{Tc}$  for SLN identification.

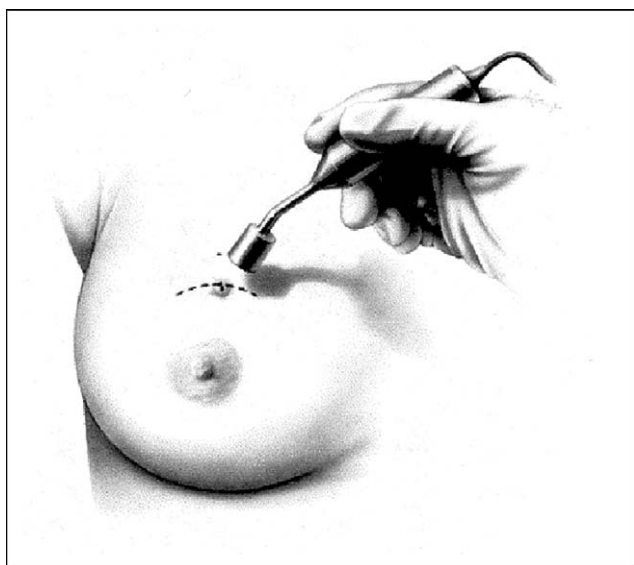
isotopes (Figs. 2 and 3) can be accomplished in the same patient with the same gamma probe. With the probe set on the  $^{125}\text{I}$  setting, the handheld gamma counter is scanned over the breast until the focus of intense uptake is detected. The point of greatest activity is easily located, allowing the incision to be strategically placed directly over the lesion, unlike with WLBB (Fig. 4). The surgeon receives constant audible feedback from the gamma probe during the procedure. This allows for continuous reorientation in real time (Fig. 5). The distal tip of the wire is unknown with WLBB, and there is some guesswork involved in estimating when the dissection is beyond the target lesion or tip of the wire. Judging the location and depth of the lesion is not an issue

with the RSL procedure, because the surgeon is clearly aware when he or she is deep to the seed and can safely come under the lesion.

The gamma probe is used to confirm that the seed is contained within the resected specimen, and the lack of  $^{125}\text{I}$  activity within the breast after resection also verifies that the seed and lesion have been removed. The excised tissue is then submitted for specimen radiography. Obtaining a specimen radiograph provides additional confirmation that the radioactive seed has been excised and confirms that a survey of the operating room is not necessary. Pathology then retrieves the seed during the intraoperative gross examination of the specimen. The seed is placed into a lead con-



**Figure 3** Gamma probe settings to detect  $^{125}\text{I}$  for intraoperative localization of the radioactive seed.



**Figure 4** Gamma probe used to detect  $^{125}\text{I}$  point source in the breast and direct lumpectomy to the target lesion. (Reprinted with permission from *Ann Surg Oncol*.<sup>15</sup>)

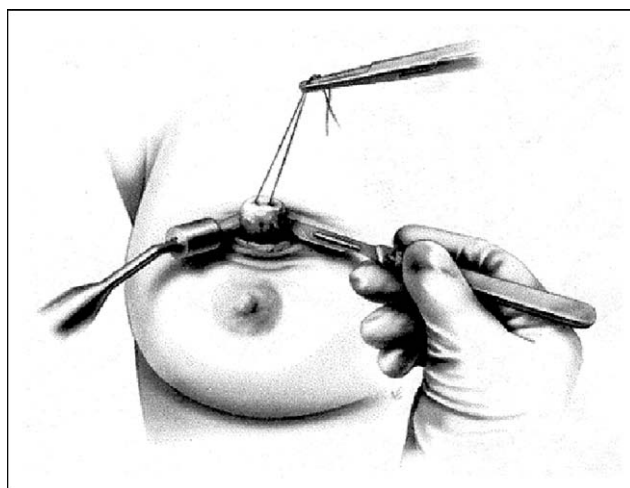
tainer and returned to nuclear medicine for long-term decay. The seed has a sturdy outer titanium shell. However, care must be taken during gross processing of the specimen to not cut into the seed. There is a theoretical risk that the  $^{125}\text{I}$  could become airborne if the seed is cut. Contamination remains highly unlikely, because current seeds have the  $^{125}\text{I}$  actually covalently bound in a halide silver reaction to a silver wire or ion exchange resin and encased in a titanium shell. There may be a very small shard of the titanium broken off, but airborne or solubilized  $^{125}\text{I}$  is extremely unlikely. Protocols must be in place to ensure tracking of the seed throughout the process. The loss of a radioactive seed must be avoided. In >300 procedures performed at the Mayo Clinic (Scottsdale, AZ) and an additional 175 cases at the H. Lee Moffitt Cancer Center (Tampa, FL), all seeds were successfully retrieved. In 475 RSL procedures reported in the literature to date, the seeds have been successfully retrieved 100% of the time.<sup>1,14,15</sup> We are aware of one case of a seed successfully removed from a patient but unfortunately lost after specimen radiography and not returned to nuclear medicine. As a result, we have employed further safety steps to avoid this in the future.

### Logistic and safety issues

Application for the use of any radioactive material and regulation of radioactive substances is carried out at the state level. The application of radioactive seeds for the localization of breast lesions was the first new radioactive technology to be selected by the Organization of Agreement States (OAS; <http://www.agreementstates.org>) for the development of a strategy to have multistate approval. The OAS is composed of 38 states that work together with the US Nuclear Regulatory Commission (NRC) to regulate ra-

dioactive material. A working group from the OAS developed the first set of guidelines that was accepted by all states in the OAS for approval for seeds for RSL breast procedures.

The use of a sealed radioactive source in the United States must comply with the NRC's guidelines. In 2006, the NRC issued a regulatory summary to inform addressees of the availability of guidance on RSL procedures. Guidance can be viewed through the NRC's medical user's licensee toolkit (<http://www.nrc.gov/materials/miau/med-use-toolkit/seed-localization.html>). Currently, the use of radioactive seeds for therapy is regulated under the NRC's 10 CFR 35.400, "use of sources for manual brachytherapy." However, because the seeds in RSL procedures are not intended to deliver therapeutic doses, they are regulated under 10 CFR 35.1000, "other medical uses," and the equivalent OAS regulations. The implantation, excision, and recovery of seeds should all fall under the same radioactive materials license. Wires can be placed and removed at any facility. A seed can also be placed at any facility that has a license to do so. However, if pathology services are used that are separate from the institution at which a seed is placed, it must be ensured that the pathology laboratory has a radioactive material license authorizing the receipt and handling of the seed contained in the specimen. As for disposal, seeds generally must be retrieved by the licensed institution and disposed of by the licensed institution. If tissue containing a seed is removed to be sent to another institution for analysis, the seed must be removed first. Otherwise, all Department of Transportation regulations apply to sending seeds over the highway to another licensed institution to do the analysis. In all, it is best for an institution to do all of it: place, retrieve, and dispose of seeds (disposal meaning sending back to the vendor). Therefore, it is mandatory for ambulatory surgery centers without radioactive materials licenses to collaborate with facilities that have them. At present, wire



**Figure 5** Lumpectomy performed with constant feedback from the gamma probe allowing a uniform lumpectomy specimen. (Reprinted with permission from *Ann Surg Oncol*.<sup>15</sup>)

**Table 1** Trials comparing intraoperative margin status and final margin status of wire-localized lumpectomies versus radioactive seed-localized lumpectomies and incidence of identifying the SLN during radioactive seed-guided lumpectomies

Study	Year	Wire (n)	First intraoperative margin positive	Final margin positive	Seeds (n)	First intraoperative margin positive	Final margin positive	SLN identified (seed cases)
Gray et al <sup>1</sup>	2001	26	57%	NA	35	26%	NA	97%
Cox et al <sup>15</sup>	2003	NA	NA	NA	64	41%	27%	NA
Gray et al <sup>19</sup>	2004	79	46%	24%	83	26%	10%	100%
Hughes et al <sup>12</sup>	2008	99	46%	25%	383	27%	8%	100%

NA = not available.

localization may logistically be the simplest approach in these settings.

Minnesota was regulated by the NRC until recently, and now, like Arizona and Florida, it is an OAS agreement state, which is becoming the national trend.<sup>1</sup> Any leaked sources or misuse of a seed must be reported to the agency that regulates radioactive material in that state.

Surgeons should obtain institutional radiation safety officer approval to perform RSL as well as proper safety training in the use and handling of radioactive seeds. Each institution's radiation safety committee or radiation safety officer must ensure that safe handling protocols are implemented and that all users have radiation safety education appropriate to their levels of responsibility. Staff members who use or handle radioactive materials must be properly trained on how to protect themselves, how to minimize their doses, and what to do in an emergency.<sup>16,17</sup> Authorized users (usually nuclear medicine physicians or radiologists) must be certified by boards that are recognized by the regulator.

The seed strength at the time of placement should be <3.7 MBq. The exposure of the skin of the breast for a seed excised within 24 hours is approximately equivalent to 2 radiographs.<sup>14</sup> No special instructions need to be given to patients while radioactive seeds are in place, because <sup>125</sup>I seed activity is <74 MBq, as listed in column 1 of Table 1 of the NRC guide and section 8.39. In the original 1999 pilot study, the radiation exposure to the patient, radiologist, surgeon, pathologist, and ancillary staff was documented to be minimal by the use of radiation badges and rings worn throughout the procedure.<sup>18</sup> In a larger series of >300 cases, badge monitoring also showed no increase in physician or technologist exposure.<sup>14</sup> The radiation exposure decreases as the inverse square of the distance from the point source. The radiation dose to the surrounding breast tissue on the basis of duration of exposure has been calculated by the group from the Mayo Clinic in Scottsdale and is depicted in Table 2.

**Experience to date**

In 1999, a pilot study was completed at the H. Lee Moffitt Cancer Center consisting of 25 patients who under-

went RSL excisional breast biopsy.<sup>18</sup> This study demonstrated RSL as a safe means of localizing and excising breast lesions. The operative time from incision to specimen removal was 4.60 ± .49 minutes (range, 1–8 minutes). Specimen radiography confirmed the retrieval of the lesions in all cases. The seed and target lesion were successfully removed by the surgeon with definitive intraoperative confirmation by the pathologist 100% of the time.

After demonstrating the safety and efficacy of RSL excisional breast biopsy and/or lumpectomy in a pilot study, a randomized prospective trial was undertaken and reported in the *Annals of Surgical Oncology* in 2001.<sup>1</sup> Ninety-seven patients with nonpalpable breast lesions were randomized to RSL or WLBB. This study demonstrated that RSL was as effective as WLBB for the excision of nonpalpable breast lesions, and it reduced the incidence of pathologically involved margins of excision. Fewer RSL patients required reexcision of margins (26% vs 57%, respectively, *P* = .02). This is a consistent finding in the trials to date and is reflected in Table 1. The study also reported no significant difference in surgical excision times (5.4 vs 6.1 minutes, *P* = .28) or the ease of the procedure as reported by surgeons (2.95 vs 2.97, *P* = .96), radiologists (1.98 vs 1.75, *P* = .63), and patients (2.59 vs 2.61, *P* = .97).

In 2003, Cox et al<sup>15</sup> reported on 124 patients undergoing RSL breast procedures with the elimination of specimen radiography. One of the endpoints of the trial was to identify which lesions could be identified grossly by the pathologist,

**Table 2** Peak radiation dose to breast after the insertion of a 3.7-MBq <sup>125</sup>I seed

Time since insertion (h)	Peak radiation dose (cGy)					
	r = 1 cm	r = 1.5 cm	r = 2 cm	r = 3 cm	r = 4 cm	r = 5 cm
1	.12	.05	.02	.01	.01	.01
24	2.78	1.12	.57	.20	.09	.04
48	5.55	2.24	1.14	.39	.17	.08
72	8.33	3.36	1.70	.59	.26	.12
96	11.10	4.49	2.27	.78	.35	.16
120	13.90	5.61	2.83	.98	.43	.20

Reprinted with permission from *Acad Radiol*.<sup>14</sup>

avoid specimen radiography. In this prospective study, specimen radiography could be eliminated in 79% of the cases. Seventy-seven percent of the remaining lesions not grossly identified by the pathologist were microcalcifications. Only 51% of the patients who underwent RSL for microcalcifications could avoid specimen radiography. As would be expected, avoiding specimen radiography reduced operative times. No seed migration was documented, and the seeds were again retrieved in 100% of cases.

The group at the Mayo Clinic in Scottsdale performed 100 consecutive RSL breast procedures and compared them with 100 consecutive preceding WLBB procedures. Sixty-eight percent of the patients underwent radiologic placement of the seeds  $\geq 1$  day before the operative day. The incidence of positive margins was reduced from 24% to 10% ( $P = .01$ ). The convenience of the process was rated higher for patients having seeds placed  $\geq 1$  day before the procedure.<sup>19</sup> Since that time, the same group has reported on a validation trial of 383 consecutive RSL procedures.<sup>12</sup> This trial included 3 sites, and these cases were compared with 99 WLBB procedures, which served as controls. Negative margins on first specimens and final negative margins were statistically more likely in the RSL group compared with the WLBB group ( $P < .001$ ). This was not a randomized study, and all control patients were chosen from only one of the sites. Despite the large numbers and excellent results, because each site performed intraoperative pathologic analysis differently, it is possible that the difference in intraoperative pathological analysis contributed to the difference in the margin positivity rate.

RSL has recently been reported as a technique to mark the tumor bed before neoadjuvant chemotherapy, with the seed also serving as the intraoperative localization device when the patient undergoes surgery months later. This is possible because of the long half-life of the seed. In the 14 neoadjuvant breast cancer patients included in the study, all underwent breast-conserving therapy. In 86% of the patients, the tumors were no longer palpable, and in 36%, the  $^{125}\text{I}$  seeds were the only remaining evidence of the original tumors.<sup>13</sup>

In all the studies in which the RSL procedures were performed in concert with SLN biopsies, the success rates have been excellent; specifically, the SLNs have been identified in 371 of the 372 cases reported in the literature to date.<sup>1,12,19</sup>

## Current issues

### Patents

Currently, there is a patent held (patent number 6,496,717) for RSL of imaged lesions. There are also two additional patents pending related to RSL (patent numbers 10,292,377 and 11,445,819). These patents do not restrict the use of seeds by any individual but were obtained to

increase the availability of  $^{125}\text{I}$  seeds and to make the radio-guided localization procedure marketable to physicians. Because the  $^{125}\text{I}$  seed for nonpalpable lesions is not used for therapeutic purposes, and the amount of radiation is minimal, it is licensed with the NRC under "other medical uses." This broad definition potentially enables other practitioners to use the seed localization technique in other areas of medicine. This methodology could easily be applicable for the localization of lesions in any area reachable with a needle, such as the breast, liver, brain, lung, colon, uterus, prostate, kidney, soft tissues, muscle, bone, and so on.

### Current utilization and billing

Several centers in the United States are actively using this approach as a standard for the localization of radiographic breast lesions requiring surgical excision. The primary hurdle that currently exists to the standard implementation of RSL nationwide is reimbursement for the radiologic localization procedure. Presently, there is no Current Procedural Terminology (CPT) code for the placement of the radioactive seed that bills to Medicare. CPT code 19499 can be used for a nominal fee but not a Medicare fee. WLBB uses CPT code 19290, which is associated with a Medicare fee. This CPT code has the description "preoperative placement of needle localization wire, breast" and is specific to wire localization. Thus, pending approval of a specific CPT code for RSL, reimbursement levels can be maintained for non-Medicare patients, but for Medicare patients, a miscellaneous CPT code must be used for the radiologic localization procedure.

The CPT code for the surgical procedure is unchanged, and code 19125 or 19126 is used: "excision of breast lesion(s) identified by preoperative placement of radiological marker," single or multiple, respectively. These codes do not specify the type of radiologic marker, and therefore these codes are appropriate whether a wire or radioactive seed has been placed.

Because nearly all surgeons performing breast surgery are familiar with radio-guided surgery through experience with SLN biopsy, training in RSL is not a significant hurdle. From the radiologist's perspective, RSL uses the same techniques as wire localization and is actually easier for the radiologist because the angle of approach is not limited. RSL breast surgery therefore uses established skill sets for surgeons, radiologists, and pathologists and can therefore be learned rapidly, with a short learning curve.

### Conclusions

RSL is a viable alternative to WLBB and has several clear advantages:

1. The surgeon has precise knowledge of the location of the radiologic marker and target lesion, so incision placement is improved.

2. The radiologist's localization approach is not limited by planning for the surgeon's incision.
3. Seeds can be placed by the radiologist days in advance.

The data to date also suggests that a lower rate of positive microscopic margins can be achieved with the RSL procedure, thus decreasing the need for additional operative interventions. Furthermore, the lower rate of positive margins is accomplished while removing a smaller volume of breast tissue, likely translating into improved cosmetic outcomes. This can be a win-win situation for the patient: a decreased likelihood of needing a second operative intervention and having less breast tissue excised. Any procedure that can decrease the cost and emotional turmoil associated with breast cancer treatment, such as occurs when a patient is told postoperatively that the cancer was not completely removed, is worth exploring. This is accomplished secondarily to the more intuitive nature of RSL lumpectomies. The surgeon can receive constant feedback by the gamma probe during the procedure. This allows for continuous reorientation in real time. This appears to allow a more uniform specimen centered on the centrally located seed.

RSL is a promising approach for the resection of non-palpable radiographic breast lesions. It is superior logistically by disassociating the radiologic localization from the operating suite schedules. It is at least equivalent to WLBB in patient and medical staff safety, reliability, ease of the procedure for patients and surgeons, removing the target lesion, obtaining negative margins, avoiding a second operative intervention, and allowing for simultaneous axillary staging. Its superiority to WLBB in these areas has been demonstrated by data to date but needs to be validated in large-scale registration protocols.

## Acknowledgments

We would like to thank Heidi Walton and Kelly Classic for their review of this report to ensure that the physics and regulatory guidelines are accurate. We would also like to thank Lisa Kleis for assistance with preparation of this report.

## References

1. Gray RJ, Salud C, Nguyen K, et al. Randomized prospective evaluation of a novel technique for biopsy or lumpectomy of nonpalpable breast lesions: radioactive seed versus wire localization. *Ann Surg Oncol* 2001;8:711-5.
2. McLaughlin SA, Ochoa-Frongia LM, Patil SM, et al. Influence of frozen-section analysis of sentinel lymph node and lumpectomy margin status on reoperation rates in patients undergoing breast-conservation therapy. *J Am Coll Surg* 2008;206:76-82.
3. Jacobs L. Positive margins: the challenge continues for breast surgeons. *Ann Surg Oncol* 2008;15:1271-2.
4. O'Sullivan MJ, Li T, Freedman G, et al. The effect of multiple reexcisions on the risk of local recurrence after breast conserving surgery. *Ann Surg Oncol* 2007;14:3133-40.
5. Thompson M, Henry-Tillman R, Margulies A, et al. Hematoma-directed ultrasound-guided (HUG) breast lumpectomy. *Ann Surg Oncol* 2007;14:148-56.
6. Homer MJ, Pile-Spellman ER. Needle localization of occult breast lesions with a curved-end retractable wire: technique and pitfalls. *Radiology* 1986;161:547-8.
7. Davis PS, Wechsler RJ, Feig SA, et al. Migration of breast biopsy localization wire. *AJR Am J Roentgenol* 1988;150:787-8.
8. Homer MJ. Transection of the localization hooked wire during breast biopsy. *AJR Am J Roentgenol* 1983;141:929-30.
9. Bronstein AD, Kilcoyne RF, Moe RE. Complications of needle localization of foreign bodies and nonpalpable breast lesions. *Arch Surg* 1988;123:775-9.
10. Montrey JS, Levy JA, Brenner RJ. Wire fragments after needle localization. *AJR Am J Roentgenol* 1996;167:1267-9.
11. Ernst MF, Avenarius JK, Schuur KH, et al. Wire localization of non-palpable breast lesions: out of date? *Breast* 2002;11:408-13.
12. Hughes JH, Mason MC, Gray RJ, et al. A multi-site validation trial of radioactive seed localization as an alternative to wire localization. *Breast J* 2008;14:153-7.
13. Maaskant A, Van Riet Y, Rutten H, et al. Identification of tumor localization for breast-conserving surgery after neoadjuvant chemotherapy using radioactive seed localization. *Ann Surg Oncol* 2007;14(suppl):86.
14. Pavlicek W, Walton HA, Karstaedt PJ, et al. Radiation safety with use of I-125 seeds for localization of nonpalpable breast lesions. *Acad Radiol* 2006;13:909-15.
15. Cox CE, Furman B, Stowell N, et al. Radioactive seed localization breast biopsy and lumpectomy: can specimen radiographs be eliminated? *Ann Surg Oncol* 2003;10:1039-47.
16. US Nuclear Regulatory Commission. Standards for protection against radiation. 10 CFR 19. Washington, DC: US Government Printing Office; 1992.
17. US Nuclear Regulatory Commission. Medical use of byproduct material. 10 CFR 35. Washington, DC: US Government Printing Office; 2003.
18. Dauway EL, Sanders R, Freidland J, et al. Innovative diagnostics for breast cancer: new frontiers for the new millennium using radioactive seed localization. Presented at: 85th Annual American College of Surgeons Clinical Congress; Chicago, IL; 1999.
19. Gray RJ, Pockaj BA, Karstaedt PJ, et al. Radioactive seed localization of nonpalpable breast lesions is better than wire localization. *Am J Surg* 2004;188:377-80.